Lab 3

Bone
Ex 9, 10, 12

References

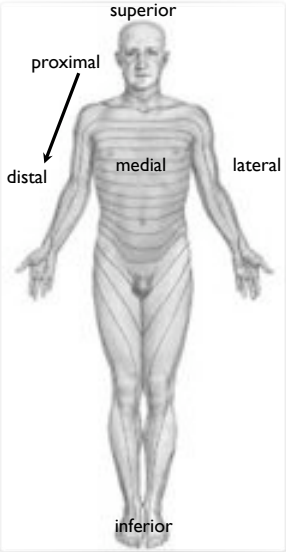

- superior/inferior
  - above or below
  - same as caudad/cepalad
- medial/lateral
  - toward or away from midline
- proximal/distal
  - closer or further away

Cartilage

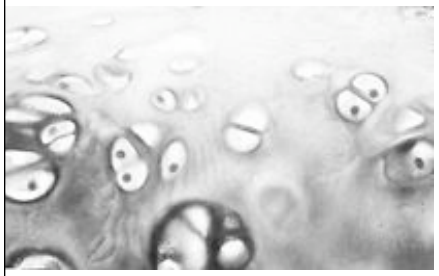

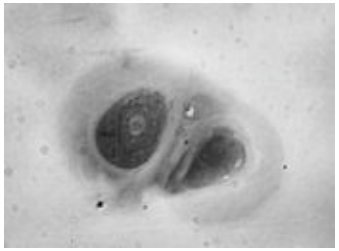

- Flexible connective tissue
  - all organic
- no blood vessels or nerves
  - slow growing
- cells reside in lacunae

Bone

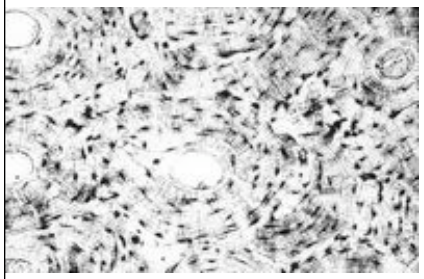

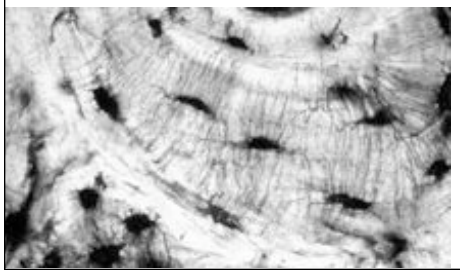

- Hard (but flexible) connective tissue
  - organic: collagen fibers
  - inorganic: calcium salts (hydroxyapetite)
- has blood vessels and nerves
  - slow growing
- cells reside in lacunae

Bone Types

- Two types of bone
  - compact bone
    - strong but heavy
    - makes up outside of all bones and majority of long bones
  - trabecular
    - light but relatively weaker
    - found in flat bones

Compact Bone

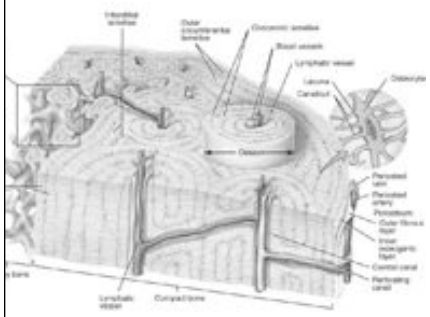

- Oseton
  - basic structural unit of compact bone
  - form in parallel to axis of force in bone
- Central (Haversian) Canal
  - blood vessel and nerves in the middle of an oseton
- Lacunae
  - osteocytes live here

Compact Bone

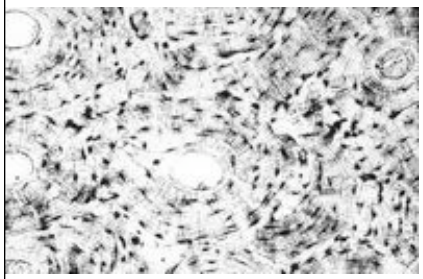

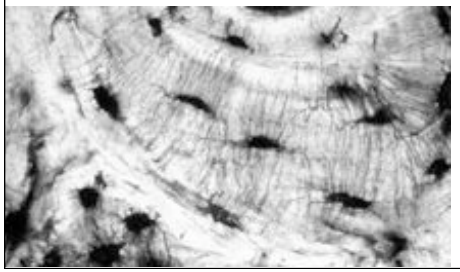

- Oseton
  - basic structural unit of compact bone
  - form in parallel to axis of force in bone
- Central Canal
  - blood vessel in the middle of an oseton
- Lacunae
  - osteocytes live here

Bone Types

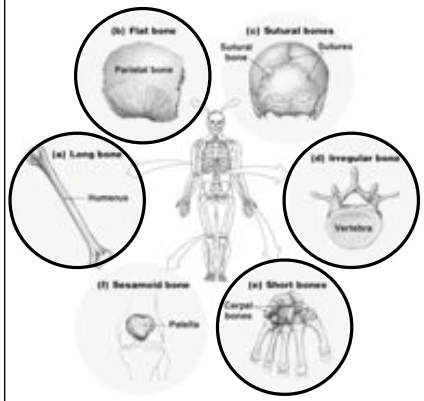

- Long Bones
  - the "classic" bone
  - forms by cartilage replacement
- Flat Bones
  - ribs, skull
  - form in a membrane
- Irregular Bones
  - vertebrae
- Short Bones
  - carpal (wrist), tarsal (ankle)

Skeletal System

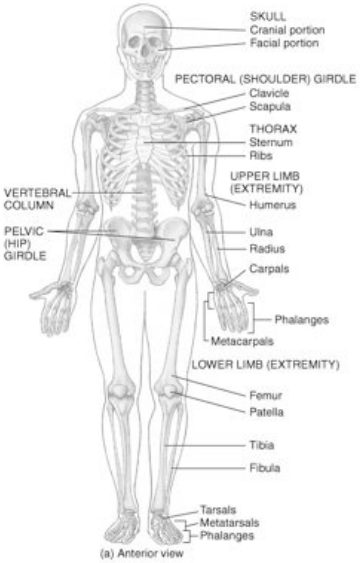

- Two Divisions
  - Axial Skeleton
    - skull
    - vertebral column
    - ribs
  - Appendicular Skeleton
    - pectoral and pelvic girdle
    - arms
    - legs

Axial Skeleton: Skull

- Frontal
- Parietal
- Occipital
- Temporal
- Sphenoid

Axial Skeleton: Skull

- Ethmoid
- Sphenoid

Axial Skeleton: Facial Bones

- Nasal
- Maxilla
- Zygomatic
- Mandible

Axial Skeleton: Facial Bones

- Maxilla
- Palatine
- Vomer
- Sphenoid
- Zygomatic Arch
  - zygomatic and temporal bone

Axial Skeleton: Vertebral Column

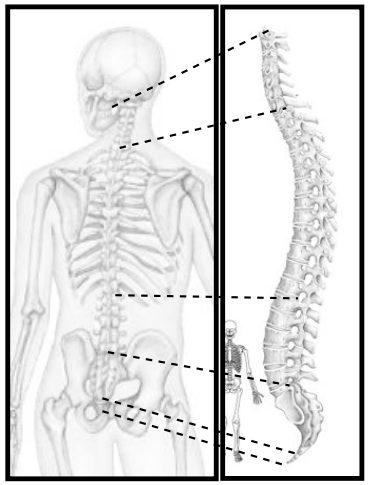

- Five Divisions
  - Cervical (neck)
    - C1-7
  - Thoracic (chest)
    - T1-12
  - Lumbar (low back)
    - L1-5
  - Sacral
  - Coccyx

Axial Skeleton: Vertebra

- Body
- Vertebral Foramen
- Transverse Process
- Spinous Process

Axial Skeleton: Vertebra

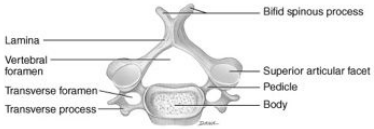

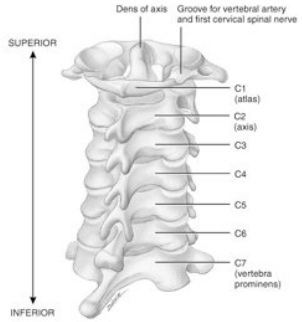

- Cervical Vertebra
  - bifid spinous process
  - small transverse process
    - transverse foramen

Axial Skeleton: Vertebra

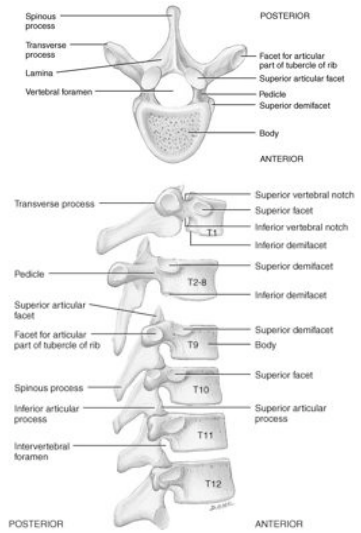

- Thoracic Vertebra
  - long spinous process
    - angled downward
  - long transverse process
  - articulations for ribs

Axial Skeleton: Vertebra

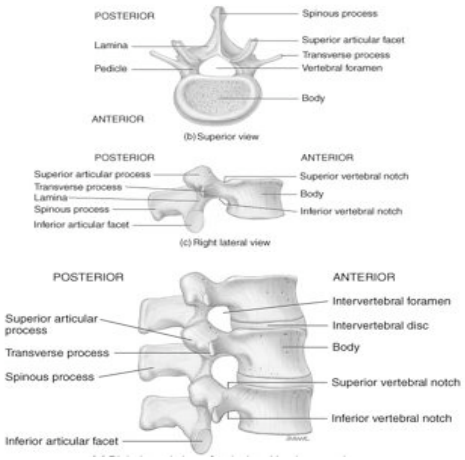

- Lumbar Vertebra
  - thick, short spinous process
  - stout transverse process
  - no articulations for ribs
  - large vertebral body

Axial Skeleton: Vertebra

Sacrum and Coccyx

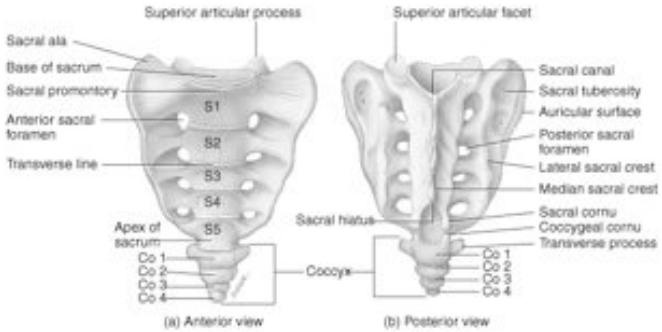

Axial Skeleton: Chest

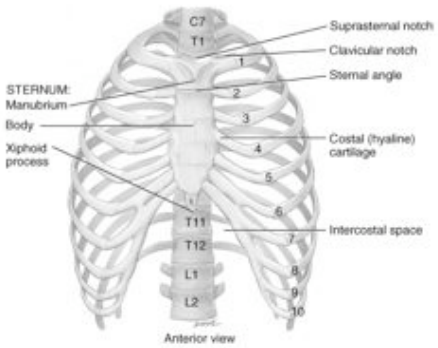

- Sternum
  - manubrium
  - body
  - xyphoid process

Axial Skeleton: Chest

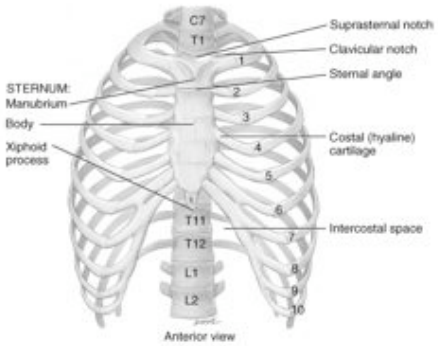

- Ribs
  - rib and costal cartilage
    - true ribs
      - attach directly to sternum
    - false ribs
      - fused cartilage to sternum
    - floating ribs
      - no sternal attachment